

## Case report:

# Mobius syndrome: The clinician's dilemma: A case report

<sup>1</sup>Dr. Apala Bhattacharya , <sup>2</sup>Dr. Aipta Bhattacharya , <sup>3</sup>Dr. Anchal Kumari

<sup>1</sup>Assistant Professor, Regional Institute of Ophthalmology, Medical College, Kolkata

<sup>2</sup>Assistant Professor, Department of Anatomy, Institute of Post Graduate medical Education & Research (IPGME&R), Kolkata.

<sup>3</sup>Post graduate trainee, Regional institute of Ophthalmology , Medical College, Kolkata.

Corresponding author: Dr. Apala Bhattacharya

---

## Abstract

In this case report the authors aim to present a case of Mobius syndrome which is a rare disorder having limited number of cases worldwide. The case presented with a combination of horizontal gaze palsy associated with seventh cranial nerve palsy and musculoskeletal deformities fitting exactly the set criteria for its diagnosis. It shows how an apparently innocuous ophthalmological disorder can actually be the tip of an iceberg of a multisystem disorder and hence can lead to diagnostic confusion.

Keywords: Mobius syndrome

---

## Introduction

Horizontal gaze palsy is usually due to lesions of the pons<sup>1</sup>. Palsy of all types of horizontal movements implicates the abducens nucleus, whereas palsies of saccades alone are due to lesions of the parapontine reticular formation. Congenital syndromes with horizontal gaze palsies include Mobius Syndrome , Cogan congenital ocular motor apraxia, and horizontal gaze palsy with progressive scoliosis. Horizontal gaze palsy with progressive scoliosis is due to mutations in the ROBO3 gene. <sup>2</sup>Moebius syndrome consists of congenital complete or partial facial nerve palsy with or without paralysis of other cranial nerves (most commonly an abducens paralysis) and often associated with other malformations of the limbs and orofacial structures .Exact pathogenesis of the Moebius syndrome is still an enigma, though it is

now widely accepted that an in utero insult to the brainstem is often the cause.<sup>3</sup>

Hallmarks of diagnosis:

Based on the observations of several authors on this subject<sup>4-6</sup>, the accepted criteria for diagnosis of Mobius syndrome are:

1. Facial palsy and absent or abnormal horizontal eye movements, not always bilateral
2. Limb malformations (syndactyly, brachydactyly, absent digits or congenital talipes equinovarus) are often present.
3. The following additional clinical features in association with complete or partial facial nerve (VII) paralysis may also be present and should be helpful in making a clinical diagnosis of Moebius syndrome: bilateral or unilateral ocular nerve palsies (commonly of

the abducens (VI) and less commonly of the oculomotor (III) and trochlear (IV) nerves); hypoplasia of the tongue owing to hypoglossal (XII) nerve paralysis; swallowing and speech difficulties owing to trigeminal (V), glossopharyngeal (IX), and vagus (X) nerve palsies; malformations of the orofacial structures (bifid uvula, micrognathia, and ear deformities); other anomalies of the musculoskeletal system, for example, absence of the sternal head of the pectoralis major, rib defects, and brachial muscle defects.

### Case presentation

A 7 years old male patient presented to the out patient's department of The Regional Institute of Ophthalmology , medical College Kolkata on the 5<sup>th</sup> of July , 2014 with the chief complaint of inability to move both of his eyes ever since his birth.

On examination the following findings were noted:

- Visual acuity:6/6-Both eyes(Snellen's chart for distant vision) and N6 Both eyes ( Jegger's chart for near vision)
- Conjunctiva:
- Cornea
- Anterior chamber
- Pupil
- Lens
- Fundus: Vertical -cup disc ratio 0.2 Macula and rest of peripheral retina within normal limits and no significant finding was noted.
- Ocular movements:

Within normal limits

Bilateral horizontal gaze palsy. Movements in the vertical meridian was normal. Eyes are straight in normal gaze. No phoria was revealed with cover -uncover

Test. Absence of nystagmus.

- Other Notable findings:
  - Bilateral facial nerve palsy:
    - ❖ Absence of forehead wrinkling.
    - ❖ Inability to fully close both eyelids.
    - ❖ Absence of nasolabial furrows on both sides.
    - ❖ Expressionless face.
  - Polydactyly in Left hand ( Six fingers in the left hand).

### Significant past medical history

- At term normal delivery with breech presentation.
- Milestones of development were a bit delayed according to mother's observation but no medical corroborative evidence could be produced.
- The child's intelligence level seemed to be below normal , most likely due to the lack of expressions owing to the facial nerve palsy. Psychological assessment carried out by experts in the psychiatry department revealed no significant abnormality pertaining to intelligence.
- He had a history of Ostium secundum type of Atrial Septal defect which required no surgical therapy and currently no cardiac abnormality exists.
- Congenital talipes Equinovarus is present for which he is undergoing treatment..

- General survey and physical examination revealed no detectable anomaly related to other musculoskeletal or gonadal disorders. His height was 122 centimetres and weight was 23 kilograms which is normal for a male Indian child of this age group.<sup>7</sup>

CT Scan of the brain revealed no detectable abnormality.

A diagnosis of Mobius syndrome was made as it fitted with the set criteria for the same, namely:

- i) Bilateral Horizontal gaze palsy
  - ii) Bilateral facial palsy.
  - iii) Presence of musculoskeletal disorder, namely, bilateral CTEV and polydactyly in left hand.
- As Bell's phenomenon was present in this patient in spite of the facial nerve palsy, so there was no immediate danger of Corneal exposure. So, he was prescribed with an ocular tear substitute and was asked to report to the Eye OPD at 6 monthly intervals for evaluation and further management if required.

#### **Discussion**

Gaze palsy is a diagnostic dilemma to the medical care giver. Horizontal gaze palsy narrows down the possibilities to few probable causes which requires meticulous evaluation to come to a diagnosis. Few of the relevant possibilities are discussed here:

- **Pontine stroke with Bilateral affection of sixth nerve nuclei.**<sup>8</sup>

The patients are usually elderly individuals with bilateral horizontal gaze palsy with facial nerve palsy (As the facial nerve nucleus is closely related to the abducent nucleus in the pontine tegmentum). However locked in syndrome with motor loss is always associated with such disorders, and the mode of occurrence is sudden as opposed to a gradual onset.

- **Bilateral paramedian lesions of the parapontine reticular formation**<sup>9</sup>

It can cause bilateral horizontal saccadic palsy with normal vertical saccades. Pursuit is often affected because its pathways are nearby, but horizontal vestibulo-ocular response is normal. There can be an associated bilateral internuclear ophthalmoplegia and cranial nerve VI palsy. However there will be no facial nerve palsy as was found in this case.

- **Horizontal midbrain gaze paresis**<sup>10,1</sup>

Midbrain lesions can disrupt descending ocular motor inputs for horizontal gaze. Slow, hypometric contralateral horizontal saccades occur with either ipsi- or contra-directional pursuit impairment. Bilateral gaze palsies can also occur. The clue to midbrain origin is concurrent cranial nerve III damage and ipsilateral ataxia. Again the patients will be in the elderly age group

- **Cogan congenital ocular motor apraxia**<sup>11</sup>

Cogan type ocular motor apraxia is a rare congenital disorder characterized by a horizontal gaze paresis. The eyes do not move properly in response to stimuli or voluntarily. When affected infants are asked to fixate on an object to the side, their eyes will lag and then move in the opposite direction. Jerky head movements are the most noticeable sign of Cogan type ocular motor apraxia and are usually recognized three to four months after birth. Some individuals with Cogan type ocular motor apraxia have a brain abnormality such as underdevelopment (hypoplasia) of the corpus callosum, hypoplasia of the cerebellum, or an abnormality in the grey matter.

- **Bilateral abducent nerve palsy**

Bilateral horizontal gaze palsy associated with esotropia is related to abducent nerve palsy on both

sides. Cerebrospinal fluid abnormalities are more frequent among bilateral cases<sup>12</sup>, but generally the same causes produce unilateral and bilateral sixth nerve palsy which include, Elevated, intracranial pressure, subarachnoid space lesions, Vascular causes, Metabolic e.g. Vitamin B12 deficiency, Wernicke –korsakoff syndrome, Neoplasm (children): pontine glioma, etc.

- **Cortical gaze palsy<sup>1</sup>**

Unilateral lesions of the frontal or parietal eye fields cause only subtle abnormalities of eye movements that require recordings to detect. Bilateral parietal or frontal lesions are more likely to impair gaze but usually in all directions.

The case under study thus corroborates well with our diagnosis of Mobius syndrome. The case is not unique, nevertheless it is very interesting as this syndrome is not only rare but the pathophysiology is even more elusive even to this day. Various authors have come up with various pathophysiologies for this rare anomaly ranging from degenerative brainstem lesions to dysplastic or aplastic muscular or extracranial nerve lesions.<sup>3</sup> Magda Lahorgue Nunes<sup>13</sup> et al. came up with a very interesting association between Mobius syndrome and Misoprostol use in pregnancy. This makes it necessary to undertake diligent studies of this anomaly to gain more insights about its pathophysiology.

FIG.1. HEAD TURNING TO COMPENSATE FOR INABILITY TO MOVE HIS EYES TOWARDS VISUAL STIMULI.

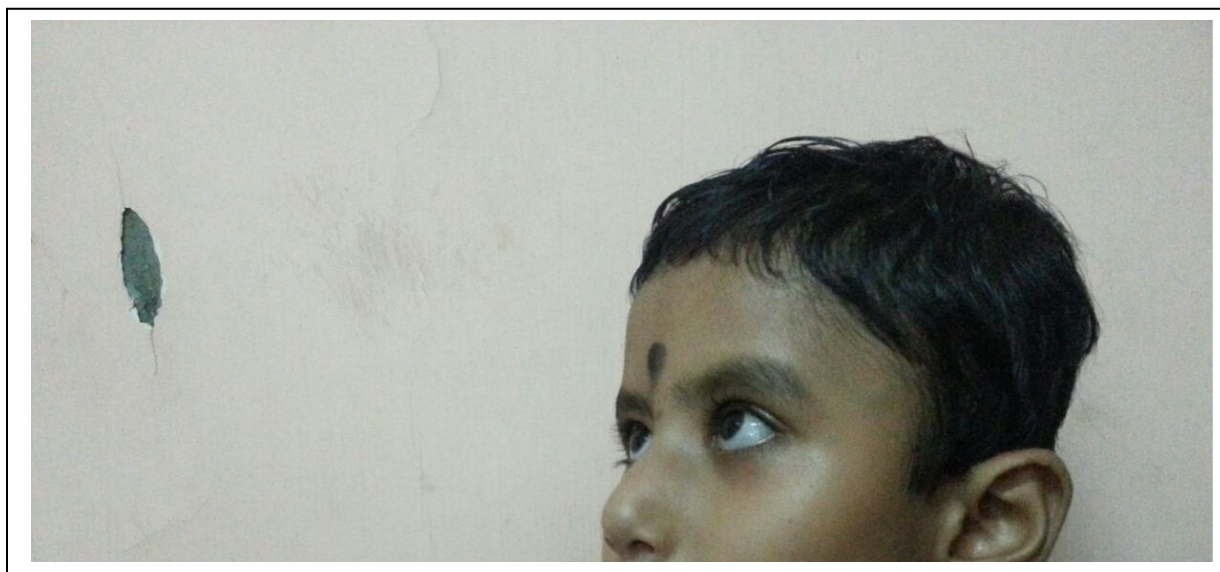


FIG.2.FEATURES OF FACIAL NERVE PALSY WITH POSITIVE BELL'S PHENOMENON

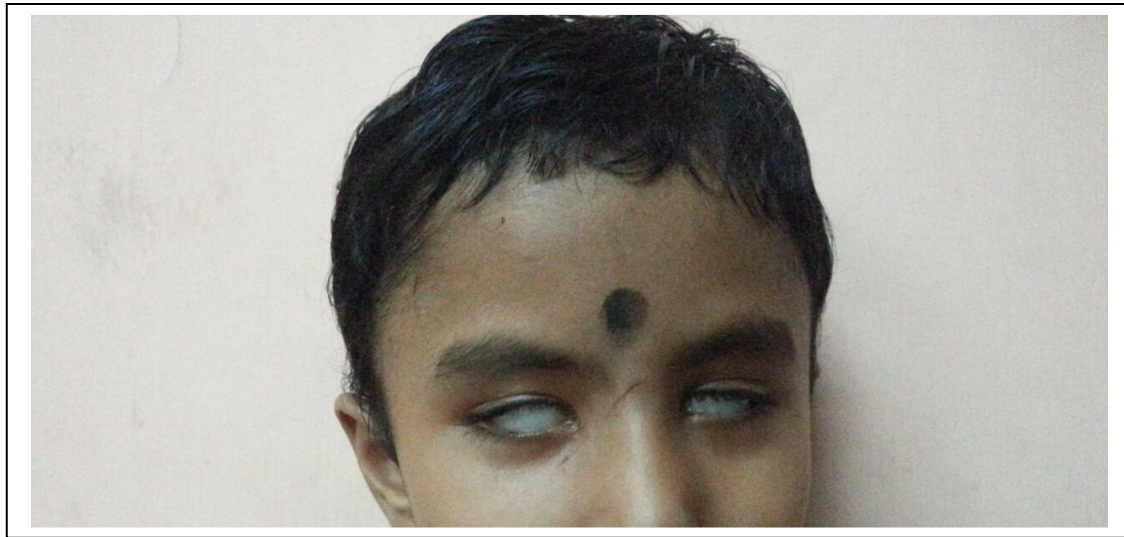
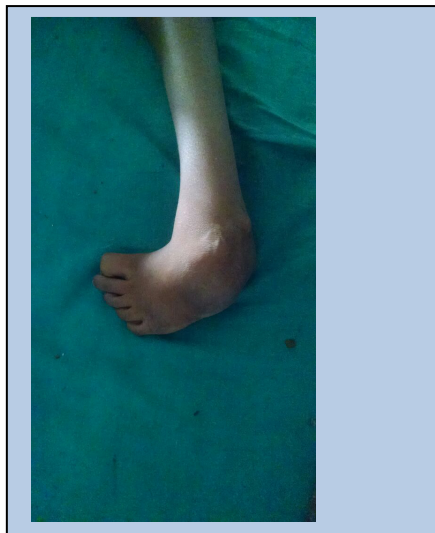


FIG.3.CONGENITAL TALIPES EQUINOVARUS IN OUR PATIENT.



### References

1. Neurology Medlink .Clinical Summary,Horizontal Gaze Palsy.Contributers: Heather E Moss MD PhD, author.James Goodwin MD,.Publication dates.Originally released July 19, 2001; last updated March 5, 2014; expires March 5, 2017.
- 2.Kumar Dhavendra,Syndrome of the month, Moebius syndrome.J Med Genet,Edited by D.Donnai and R. winter,1990;27:122-126.
3. Samuel E. Pitner, James E. Edwards, and William F. McCormick, Observations on the pathology of the Moebius syndrome. J. Neurol. Neurosurg. Psychiat., 1965, 28, 362

4. Hendersen JL. The congenital facial diplegia syndrome. *Brain* 1939;62:381-403.
- 5 Richards RN. The Moebius syndrome. *J Bone J3oint Surg [Am]* 1953;35:437-44.
6. Baraitser M. Genetics of Moebius syndrome. *J Med Genet* 1977;14:41 5-7.
7. Khadilkar Vaman, Yadav Sangeeta, et al. Revised IAP Growth Charts for Height, Weight and Body Mass Index for 5- to 18-year-old Indian Children. Indian Academy of Pediatrics Growth Chart committee.: Volume-52, January 15, 2015.
8. Felicio AC, Bichuetti DB, Marin LF. Bilateral horizontal gaze palsy with unilateral peripheral facial paralysis caused by pontine tegmentum infarction. *J Stroke Cerebrovasc Dis* 2009; 18:244-6.
9. Baloh RW, et al, Eye movements in patients with absent voluntary horizontal gaze. *Ann Neurol* 1985;17:283.
10. Fong CS, Claude's syndrome associated with supranuclear horizontal gaze palsy caused dorsomedial midbrain infarction, *Acta Neurol Taiwan*, 2005 Sep;14(3):147-50
11. Internet source: <http://www.rarediseases.org/rare-disease-information/rare-diseases/byID/1038/viewFullReport>
12. Keane JR, Bilateral sixth nerve palsy . Analysis of 125 cases.. *Arch Neurol*, 1976 Oct;33(10):681-3
13. Magda Lahorgue Nunes, Maurício A. G. Friedrich, Luiz Fernando Loch, Association Of Misoprostol, Moebius Syndrome And Congenital Central Alveolar Hypoventilation , Case Report: *Arq Neuropsiquiatr* 1999;57(1):88-91